

RECNAC

RECNAC is a project of the Bio-Communications Research Institute, a division of
The Center for the Improvement of Human Functioning International

3100 North Hillside Avenue • Wichita • Kansas 67219 U.S.A.
Tel: 001 316 682 3100 • Fax: 001 316 682 5054

© Copyright 1997, The RECNAC Project

Intravenous Ascorbate as a Chemotherapeutic and Biologic Response Modifying Agent

Introduction

For over 15 years we have studied high dose intravenous ascorbic acid (IAA) as an adjunctive therapy for cancer patients. Initially, doses of 15g per infusion were used, once or twice per week. These doses improved patients' sense of well being, reduced pain, and in many cases prolonged life beyond prognostications of oncologists.

Twelve years ago, we used infusions of 30 grams of IAA, twice per week, and found that metastatic lesions in the lung and liver of a man with a primary renal cell carcinoma disappeared in a matter of weeks (1). At that time we believed IAA was useful for patients with cancer solely through two biological response modifier mechanisms: increased production of extracellular collagen ("walling off" the tumor as proposed by Cameron and Pauling) and enhancement of immune function. We subsequently reported a case of resolution of bone metastases in a patient with primary breast cancer (1A) using infusions of 100 grams, once or twice per week (2).

In a recent publication (3) we presented evidence that ascorbic acid and its salts (AA) could be more than biological response modifiers. We found that AA is preferentially toxic to tumor cells - suggesting that it could be useful as a chemotherapeutic agent. Preferential toxicity occurred *in vitro* in multiple tumor cell types. We also presented data suggesting that plasma concentrations of ascorbate required for killing tumor cells were achievable in humans. Others have described *in vivo* toxicity in multiple tumor types and animal models (4-8).

Here we wish to summarize our experience using IAA for approximately 50 patients with cancer. We include our protocol, precautions, and case studies of two patients treated for metastatic renal cell carcinoma.

Treatment rationale

From our studies (3) we concluded that:

1. Tumor cells are more susceptible to the effects of high-dose, ascorbate-induced peroxidation products because of a relative catalase deficiency; and,
2. Concentrations of ascorbate high enough to kill tumor cells likely can be achieved in humans.

Subsequently we tested samples of human serum from patients receiving IAA, and confirmed that AA concentrations can reach levels that are cytotoxic to tumor cells *in vitro*. Using densely populated monolayers, three-dimensional hollow-fiber tumor models, and human serum as a growth medium to closely mimic what occurs *in vivo*, we found that an AA concentration of 400 mg/dL effectively kills most tumor cell types. Originally we reported that a concentration of 40 mg/dL was adequate (3). Those early data were generated from *in vitro* studies using sparsely populated cell monolayers and standard tissue culture medium.

Figure 1 shows the responses to increasing doses of ascorbate of four human tumour cell lines grown in dense monolayers in a medium of human serum.

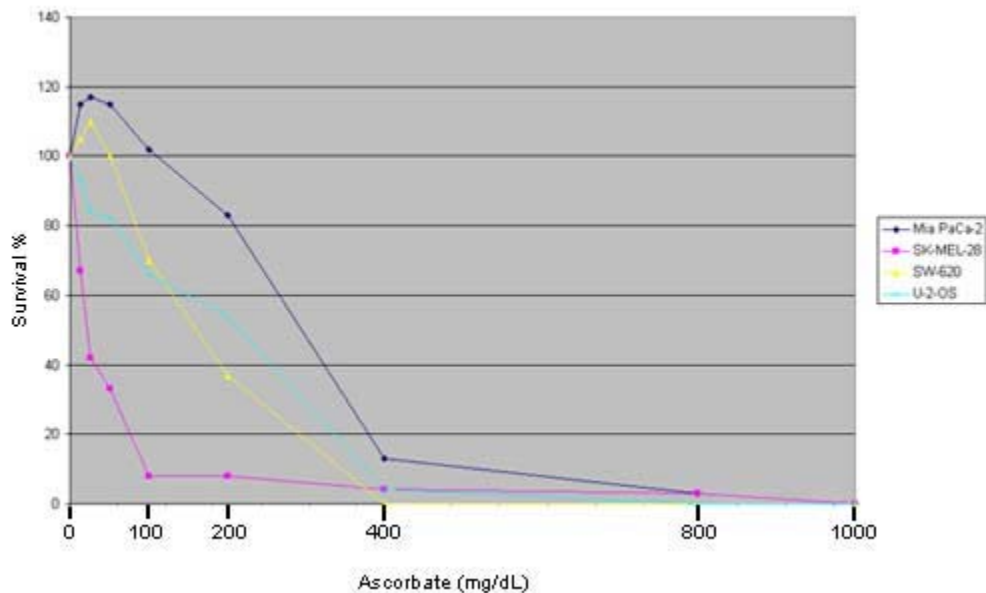


Figure 1. Response to sodium ascorbate (mean of 12 samples) of tumour cell lines Mia PaCa-2 (human pancreatic carcinoma), SK-MEL-28 (human melanoma), SW-620 (human colon carcinoma), and U-2-OS (human osteogenic sarcoma), all from ATCC, Rockville, MD. Results reflect total viable cells. Maintenance medium was DMEM High-glucose culture medium (Irvine Sci.) w/10% heat-inactivated fetal calf serum + antibiotics + Fungizone, 5% CO₂ humidified incubator at 37 deg. C. Experimental medium was human serum from patients with diagnoses of respective human tumours. Cultured for three days after supplementation of ascorbate. Seeded with 24,000 cells/well in 96-well culture plates (Nunc). Absolute quantitation of live cells determined using previously described microplate fluorometer method (16).

Figure 2 depicts plasma ascorbate levels of three representative patients given 65 grams of ascorbate over 65 minutes. Patient 1 with a localised prostate cancer was clinically well and had received IAA in the past; he achieved a peak plasma concentration of 702mg/dL. Patients 2 and 3 had diagnoses of non-Hodgkin's lymphoma, and metastatic carcinoma of the jejunum, respectively. Both had received several IAA infusions at the time of study, yet achieved lower plasma AA concentrations of 309mg/dL (patient 3) and 396mg/dL (patient 2).

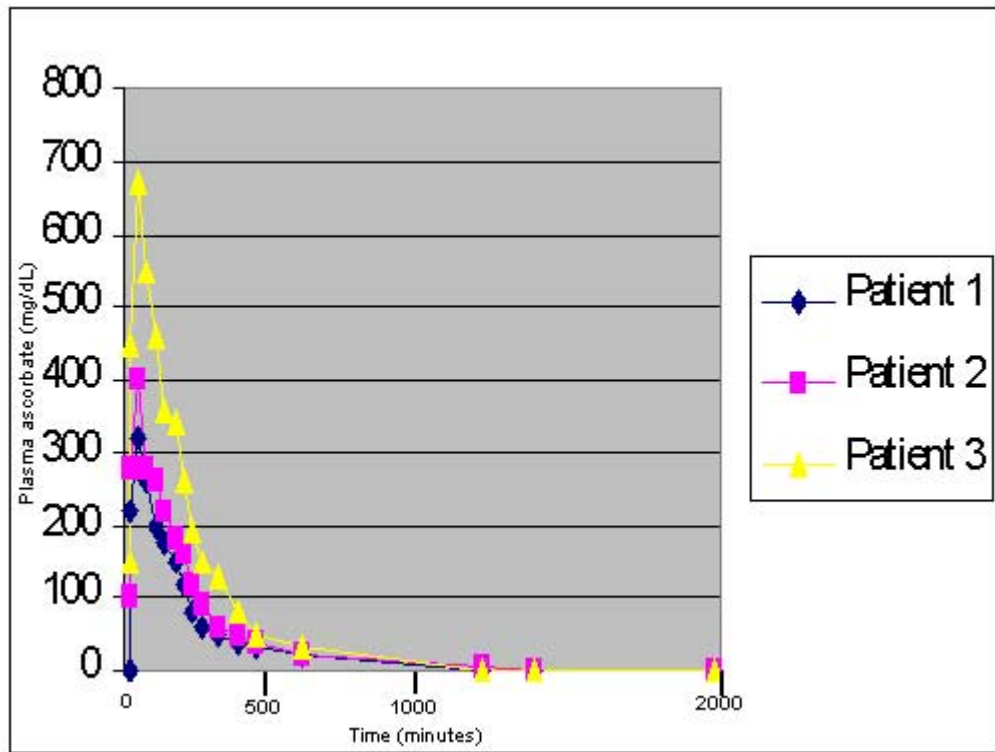


Figure 2. Plasma ascorbate concentrations during infusion of 65 grams ascorbic acid in 500ml sterile water at a rate of one gram AA per minute. Whole blood was taken via a heparin lock from the antecubital vein of the arm contralateral to the arm receiving the IV infusion. Plasma AA concentrations were determined using high performance liquid chromatography. Patient 1 was a 74-year-old male who had a diagnosis of non-metastatic prostate carcinoma, who had received >30 IAA infusions in the two years prior to the study. Patient 2 was a 50-year-old male with a diagnosis of non-Hodgkin's lymphoma who had received 16 IAA infusions prior to the study. Patient 3 was a 69-year-old male with a diagnosis of metastatic carcinoma of the jejunum who had received 16 IAA infusions prior to study.

From the data in both figures 1 and 2, one can see that the concentrations required to kill tumour cells can be achieved at least briefly in human plasma. Figure 2 suggests the need to measure post-IAA plasma ascorbate concentrations to determine if patients are achieving what we expect are adequate concentrations.

Infusion Protocol

Treatment choice

Treatment of cancer with IAA should never be considered to replace an effective, proven treatment. It should only be considered in:

- Cases of treatment failure using proven methods
- Cases with no known effective treatments
- Cases in which it is used as an adjunct to proven treatments.

Because IAA treatment is experimental an appropriate informed consent form should be read, understood, and signed by the patient.

Precautions and side effects

The side effects of IAA in our experience are rare. However, there are contraindications and potential side effects to be considered.

1. Although it has been reported only once in the literature, tumor necrosis, hemorrhage and subsequent death after a single intravenous 10 gram dose of AA, as reported by Campbell and Jack (10), should be the highest priority concern for the safety of IAA for cancer patients. For this reason, we always begin with a small dose (see Infusion).
2. Another report described acute oxalate nephropathy in a patient with bilateral ureteric obstruction and renal insufficiency who received 60 gram IAA (11). We have also heard one case report of a patient with colon carcinoma, receiving daily IAA, who developed nausea and vomiting and was hospitalized for dehydration (12). Both cases show the need to ensure that patients have adequate renal function, hydration, and urinary voiding capacity. To these ends, our baseline lab tests include a serum chemistry profile and urinalysis.
3. Hemolysis can occur in patients with a red cell glucose-6-phosphate dehydrogenase (G6PD) deficiency. We therefore test G6PD on all patients before beginning IAA infusions.
4. Localized pain at the infusion site can occur if the infusion rate is too high. This is usually corrected by slowing the rate.
5. Because ascorbate is a chelating agent, some individuals may experience shaking due to low serum calcium. This is treated by a slow (1 cc per minute) intravenous push of 10 cc of calcium gluconate.
6. Rivers (13) reported that high dose IAA is contraindicated in renal insufficiency, chronic hemodialysis patients, unusual forms of iron overload, and oxalate stone formers. However, oxalate stone formation may be considered a relative contraindication. Two groups of researchers (14,15) demonstrated that magnesium oxide (300 mg/d orally) and

vitamin B6 (10 mg/d orally) inhibited oxalate stone formation in stone formers.

7. Given the amount of fluid which is used as a vehicle for the ascorbate and the sodium hydroxide/sodium bicarbonate used to adjust the pH, any condition which could be adversely affected by increased fluid or sodium is relatively contraindicated. For example: congestive heart failure, ascites, edema, etc.
8. As with any intravenous site, infiltration is always possible.
9. Ascorbate should only be given by intravenous drip. It should **never** be given IV push, as the osmolality of high doses are capable of sclerosing peripheral veins, nor should it be given intramuscularly or subcutaneously. There is always a trade-off between fluid volume and osmolality. We have found an osmolality of less than 1200 milliOsmal to be tolerated well by most patients (Table 1).

Table 1: Osmolality of various amounts of sodium ascorbate/ascorbic acid in sterile water and Ringer's Lactate (mOsm; isotonic=300mOsm). Hypotonic mixtures are underlined; useful mixtures from isotonic to 1200mOsm are in bold. An equal volume of IV solution is removed from the bag or bottle, prior to adding concentrated sodium ascorbate/ascorbic acid solution (500mg/mL).

Sodium ascorbate/ Ascorbic acid (g)	Final Volume of Sterile Water				Final Volume of Ringer's Lactate			
	250	500	750	1000	250	500	750	1000
1	<u>39</u>	<u>19</u>	<u>13</u>	<u>10</u>	336	318	312	309
15	579	<u>290</u>	<u>193</u>	<u>145</u>	843	573	481	436
30	1158	579	386	<u>290</u>	1386	843	662	572
60	2316	1158	772	579	2472	1386	1024	843
75	2895	1448	965	724	3015	1658	1205	979
100	3860	1930	1287	965	3920	2110	1507	1205

Baseline work-up

Prior to administering large quantities of ascorbate, we gather the following information for a baseline and as a way to monitor therapy:

1. Serum chemistry profile with electrolytes
2. Complete blood count with differential
3. Red blood cell G6PD
4. Urinalysis
5. Patient weight
6. Tumor type/staging
7. Appropriate serum tumor markers

8. Appropriate CT, MRI, bone scans, and x-ray imaging.

Infusion solution

In high-dose ascorbate therapy, many intravenous solutions are hypertonic. This does not seem to present a problem as long as the infusion rate is low enough and the tonicity does not exceed 1200 milliOsmal (mOsm). We generally infuse AA mixed with Ringer's lactate (RL) solution for AA amounts up to 15 gram, and in sterile water for larger amounts of AA. We presently use a sodium ascorbate/ascorbic acid mixture containing 0.91 moles of sodium per mole of ascorbate (500 mg AA/mL, pH range 5.5-7.0, Merit Pharmaceuticals, Los Angeles, California, and Maclaskey Pharmaceuticals, Wichita, Kansas). Table 1 shows the osmolalities of commonly prepared solutions.

Infusion

As indicated in the precautions, a small starting dose of 15 gram AA in 250 mL RL over 1 hour is recommended. The patient is watched closely for any adverse effects. The dose can then be gradually increased over time. The infusion rate should not exceed 1 gram AA per minute; 0.5 gram/min is well tolerated by most patients. Although there is variability due to scheduling and tolerance, a typical protocol will consist of the following infusions:

- Week 1: 1 x 15 g infusion per day, 2-3 per week
- Week 2: 1 x 30 g infusion per day, 2-3 per week
- Week 3: 1 x 65 g infusion per day, 2-3 per week

The dose is then adjusted to achieve transient plasma concentrations of 400 mg/dL, 2-3 infusions per week.

According to our working hypothesis, the goal of the infusions is to raise plasma ascorbate concentration above the tumor-cytotoxic level for as long as possible. Because the ascorbate is so readily cleared by the kidney, the optimal infusion rate will result in tumor-cytotoxic plasma levels of ascorbate for the longest time periods - and hopefull, maximum tumor cell killing.

We advise patients to orally supplement with 4 grams ascorbate daily, especially on the days when no infusions are made, to help prevent a possible scorbutic "rebound effect".

Case histories

We have seen patients with almost every type of solid tumor in our clinic. Many of them have received IAA, with various degrees of success. Our cases include a patient with cancer of the head of the pancreas who lived for 3.5 years with IAA as sole therapy, resolution of bone metastases in patients with breast cancer, many patients with non-Hodgkin's lymphoma (none of whom have died from their disease), resolution of primary liver carcinoma tumors, resolution of and reduction in size of metastatic colon carcinoma lesions, and resolution of metastatic lesions and over 3-year survival in patients with widely metastatic ovarian carcinoma. We plan to present a full compilation of cases in another communication.

We have seen only two cases of metastatic renal cell carcinoma, considered a uniformly untreatable disease. Because the results were so dramatic, people with this disease could potentially benefit the most from IAA treatment. Following are those two cases.

Case 1

A 52 year-old white female with a history of renal cell carcinoma was seen in our clinic for the first time in October, 1996.

In September 1995, shortly after diagnosis of a primary tumor in her left kidney, a nephrectomy was performed. Histology confirmed renal cell carcinoma. No evidence of metastases was found at that time. In March 1996, metastases to the lungs were found on chest x-ray film. In September 1996, a chest x-ray film revealed 4 1-to-3 cm masses in her lungs. One month later there were 8 1-to-3 cm masses in her lungs (7 in the right lung, 1 in the left).

No new medical, radiation, or surgical therapies were performed prior to her visit to our clinic in October 1996, when she began IAA therapy. Her initial dose was 15 g, which increased to 65 g after two weeks, two per week. She was also started on:

- N-acetyl cysteine (Vitamin Research Products, Carson City, NV), 500 mg 1 p.o., QD;
- beta-1,3-glucan (a macrophage stimulator, NSC-24, Nutrition Supply Corp., Carson City, NV), 2.5 mg 3 p.o. QD;

- fish oil (Super-EPA, Bronson Pharmaceuticals, St Louis, MO; 300 mg eicosatetraenoic acid, 200 mg docosahexaenoic acid), 1 p.o. TID;
- vitamin C, 9 g p.o. QD; beta-carotene (Beta Carotene 25, Miller Pharmacal Group, Inc., Carol Stream, IL), 25,000 I.U. 1 p.o. BID;
- L-threonine (The Solgar Vitamin Co, Inc., Lynbrook, NY), 500 mg p.o. QD (for a deficiency revealed by laboratory testing of serum);
- *Bacillus laterosporus* (Lateroflora, International Bio-Tech U.S.A., San Marcos, CA), 280 mg, 2 p.o. QD for intestinal *Candida albicans*;
- inositol hexaniacinate complex (Niaplex, Karuna Corp., Novato, CA; 500 mg niacin, 100 mcg chromium) 2 p.o. QD;
- and a no-refined-sugar diet.

She continued IAA treatments until June 1997 when another chest x-ray film revealed resolution of 7 of the 8 masses, and reduction in the size of the 8th. According to the medical imaging report, "The nodular infiltrates seen previously in the right lung and overlying the heart are no longer evident and the nodular infiltrate seen in left upper lung field has shown marked interval decrease in size and only vague suggestion of an approximately 1 cm density."

The patient discontinued IAA treatments in June 1997. She has continued on an oral nutrition support program since that time, and at this writing (December 1997) is well with no evidence of progression.

Case 2

In December 1985, a mass occupying the lower pole of the right kidney was discovered in a 70 year-old white male. Pathology of the mass after a radical nephrectomy confirmed renal cell carcinoma. He was followed by an oncologist at another clinic. Approximately three months after surgery, the patient's x-ray film and CT scan showed "multiple pulmonary lesions and lesions in several areas of his liver which were abnormal and periaortic lymphadenopathy."

In March 1986 the patient was seen in our clinic (1). He decided not to undergo chemotherapy. He requested and was started on IAA, 30 g twice per week.

In April 1986, six weeks after the x-ray film and CT scan studies, the oncologist's report states, " the patient returns feeling well. His exam is totally normal. His chest x-ray shows a dramatic improvement in pulmonary nodules compared to six weeks ago. The periaortic lymphadenopathy is completely resolved ... either he has had a viral infection with pulmonary lesions with lymphadenopathy that has resolved or (2) he really did have recurrent kidney cancer which is responding to your vitamin C therapy."

The oncology report in July 1996 stated, "there is no evidence of progressive cancer. He looks well ... chest x-ray today is totally normal. The pulmonary nodules are completely gone. There is no evidence of lung metastasis, liver metastasis or lymph node metastasis today, whatsoever."

In 1986 the patient received 30 g infusions twice weekly for 7 months. The treatments were then reduced to once per week for 8 more months. For an additional 6 months he received weekly, 15 g IAA infusions.

During and after treatments, the patient reported no toxicities, and his blood chemistry profiles and urine studies were normal.

The patient continued well, and was seen periodically at our clinic until early 1997 when he died, cancer-free, at age 82, 12 years after diagnosis.

Conclusions

We believe that IAA has potential as a chemotherapeutic agent. We hope our protocols for mixing and infusion of IAA, precautions to be taken before and during its use, and clinical case reports will justify further clinical trials and research with IAA for patients with metastatic disease. We do not believe it is a cure for all cancers. Although it shows promise as a sole therapy, particularly in renal cell carcinoma, it should be used primarily as an adjunct to other effective therapies.

Support

Our research is funded solely through donations from individuals. We have neither sought nor received funding from government agencies. We encourage readers to support our research. All donations to our 501 (C) 3 organization are tax-deductible.

Neil H. Riordan, P.A.-C
Hugh D. Riordan, M.D.
Ronald E. Hunninghake, M.D.
The Center for the Improvement of Human Functioning,
International, Inc.
3100 N. Hillside Ave.
Wichita, Kansas 67219

Acknowledgements: We would like to thank the RECNAAC Project scientific staff who contributed to this research: Xiaolong Meng, M.B., Paul Taylor, B.S., Jei Zhong, M.B., Kevin Alliston, M.S., and Joseph Casciari, Ph.D. We thank Don R. Davis, Ph.D., for editing this manuscript.

References

[Back](#)

1. Riordan HD, Jackson JA, Schultz M. Case study: high-dose intravenous vitamin C in the treatment of a patient with adenocarcinoma of the kidney. *J.Ortho.Med.* 1990; **5**:5-7.
2. Riordan N, Jackson JA, Riordan HD. Intravenous vitamin C in a terminal cancer patient. *J.Ortho.Med.* 1996; **11**:80-82.
3. Riordan NH, Riordan HD, Meng X, Li Y, Jackson JA. Intravenous ascorbate as a tumor cytotoxic chemotherapeutic agent. *Med. Hypotheses* 1995; **44**:207-213.
4. Cohen MH, Krasnow SH. Cure of advanced Lewis lung carcinoma (LL): A new treatment strategy. *Proceedings of AACR* 1987; **28**:416
5. Lupulesco A. Vitamin C inhibits DNA, RNA and protein synthesis in epithelial neoplastic cells. *Intl.J.Vit.Nutr.Res.* 1991; **61**:125-129.
6. Varga JM, Airoidi L. Inhibition of transplantable melanoma tumor development in mice by prophylactic administration of Ca-ascorbate. *Life Sciences* 1983; **32**:1559-1564.
7. Pierson HF, Meadows GG. Sodium ascorbate enhancement of carbidopa-levodopa methyl ester antitumor activity against pigmented B-16 melanoma. *Cancer Res.* 1983; **43**:2047-2051.
8. Chakrabarti RN, Dasgupta PS. Effects of ascorbic acid on survival and cell-mediated

- immunity in tumor bearing mice. *IRCS Med.Sci.* 1984; **12**:1147-1148.
9. Tsao CS, Dunham WB, Ping YL. *In vivo* antineoplastic activity of ascorbic acid for human mammary tumor. *In vivo* 1988; **2**:147-150.
 10. Campbell A, Jack T. Acute reactions to mega ascorbic acid therapy in malignant disease. *Scot.Med.J.* 1979; **24**:151.
 11. Wong K, Thomson C, Bailey RR, McDiarmid S, Gardner J. Acute oxalate nephropathy after a massive intravenous dose of vitamin C. *Aust.NZ.J.Med.* 1994:24.
 12. Hanson J. Personal communication, December 1, 1997.
 13. Rivers JM. Safety of high level vitamin C ingestion. In: Third Conference on AA. *Ann.NY.Acad.Sci.* 1987; **498**:95-102.
 14. Rattan V, Sidhu H, Vaidyanathan S, Thind SK, Nath R. Effect of combined supplementation of magnesium oxide and pyridoxine in calcium-oxalate stone formers. *Urol.Res.* 1994; **22**:161-5.
 15. Prien EL, Gershoff SF. Magnesium oxide-pyridoxine therapy for recurrent calcium oxalate calculi. *J.Urol.* 1974; **112**:509-512.
 16. Riordan HD, Riordan NH, Meng X, Zhong Z, and Jackson JA. Improved microplate fluorometer counting of viable tumor and normal cells. *Anticancer Res.* 1994: 927-932.

Back

The RECNAC Project is totally funded by contributions from corporations, foundations and hundreds of individuals.

Therefore RECNAC would appreciate receiving a contribution from you to support their work. The Center is a 501(C)3 medical research tax exempt organization. Every penny of your contributions is tax deductible.

Thank you.